



LESION OF THE BROAD LIGAMENT CASE REPORT

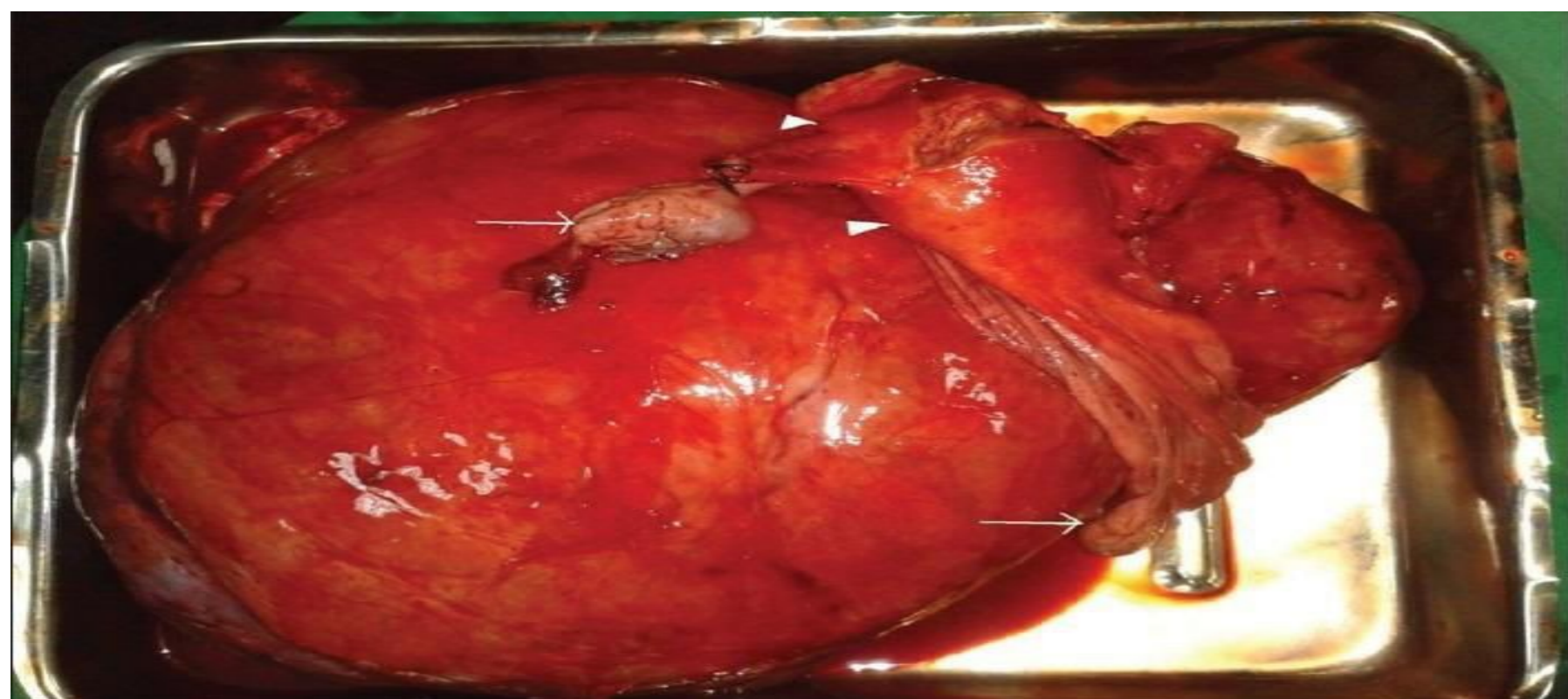


A.LIPPOLIS ,L.M. SCHONAUER , A. SGARAMELLA , M. ALBANESE
S.CAVOLATA , M.LICCHELLI , E. LOMBARDI , M. LOVERRO , E. DI NARO

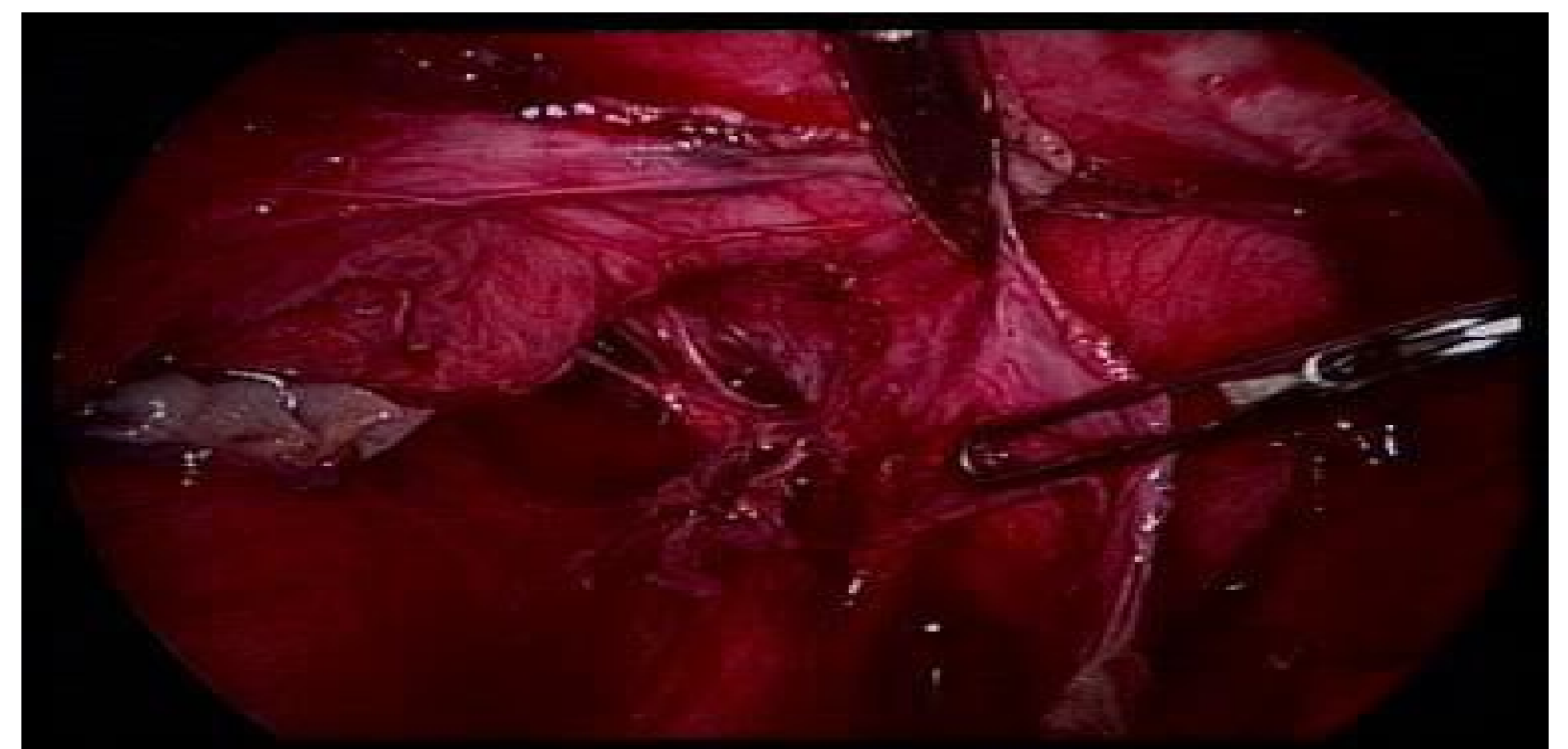
Italy, University of Bari, Department Of Biomedical Sciences And Human Oncology

INTRODUCTION

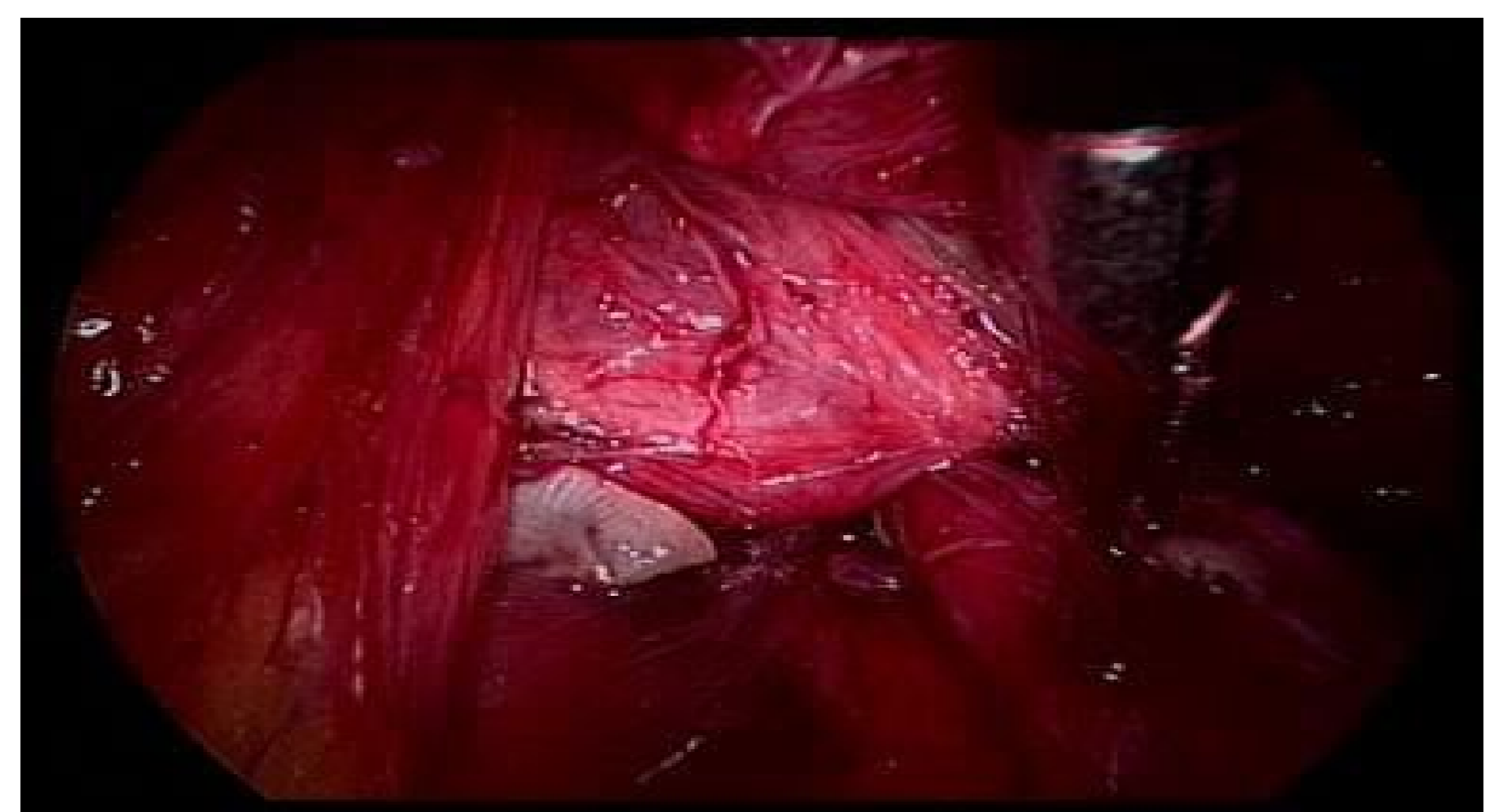Myomas are most often benign tumours of the female genital tract. Uterine fibroids are the most common myomas, while uterine cervix and intraligamentary ones are statistically less frequent. The most common histopathological form is the leiomyoma and the least common is the cellular leiomyoma (< 5%). The differential diagnosis of lesions arising in the broad ligament is quite large. Many of these lesions can be clinically interpreted before surgery as adnexal or uterine neoplasms. Although some lesions are similar to those arising in other müllerian sites, there are unique lesions as well. The lesions are uncommon and may prove challenging to clinicians



EXAMPLE OF BROAD LIGAMENT HUGE MASS



OPENING OF BROAD LIGAMENT



MASS OF THE BROAD LIGAMENT

CASE REPORT

In this case report we describe the laparoscopic surgical treatment of broad ligament lesion in a 39 years old diagnosed with uterine leiomyoma and ovarian cyst . The patient was admitted for pelvic pain . Blood tests were normal. CA 19.9 was slight raised. The other oncological markers levels were within normal limit. The patient previously underwent the removal of uterine leiomyomas and endometriosis ovarian cyst enucleation with laparotomic approach. The diagnostic imaging (ultrasound and MRI) demonstrated leiomyoma of the posterior wall of the uterus and bilateral adnexal cysts the largest of which is 12 cm in left adnexal region. The patient underwent laparoscopic surgery with the final diagnosis of cysts of the broad ligament of the left and right ovary endometrial cysts . In order to excide the left broad ligament lesion it was necessary a radical cancer surgery approach

RESULTS

The patient was discharged after four days of hospitalization and assigned to follow up at the outpatient service.

DISCUSSION

In this case , the lesion corresponded to a massive hydrosalpinx, secondary to chronic salpingitis, which deepened in the broad ligament. Moreover, the presence of a massive leiomyoma in the broad ligament, and a genital omental intestinal vast complex adhesions has become a simple surgery complex and so it was necessary a radical cancer surgery approach with isolation of the iliac vessels , identification and isolation of the ureter , nerve sparing and opening the left pararectal Okobayashi space. These lesions are uncommon and may prove challenging to clinicians and so it is necessary surgeon experience in the laparoscopic approach. Data in the literature regarding laparotomic approach versus laparoscopic are rare. Thus, though uncommon, broad ligament lesion should be considered during evaluation of adnexal masses for optimal patient management

REFERENCES

- 1] Jagtap VS, Khatib GM, Jagtap SS, Kshirsagar NS. Large leiomyoma of the broad ligament. J Med Allied Sci. 2013
- 2] Bakari F, Sulayman HU, Avidime S, Ameh N, Adesiyun AG. Huge Broad Ligament Leiomyoma: A Case Report. Case Reports in Clinical Medicine. 2015
- 3] Chmaj-Wierzchowska K, Buks J, Wierzchowski M, Szymanowski K, Opala T. Leiomyoma cellulare in the broad ligament of the uterus – case report and review of literature. Ginekol Pol. 2015
- 4] Jagtap VS, Gupta A, Kshirsagar NS. Broad Ligament Leiomyoma Mimicking As Ovarian Tumour. Sch J App Med Sci. 2014
- 5] Yuei Vi, Kaur V. Broad ligament fibroid: An unusual presentation. J K Sci. 2006
- 6] Godbole RR, Lakshmi KS, Vasant K. Rare case of giant broad ligament fibroid with myxoid degeneration. J Sci Soc. 2012;39:144–46.
- 7] Massive Broad Ligament Cellular Leiomyoma with Cystic Change: A Diagnostic Dilemma Preeti Sharma, corresponding author1 Sufian Zaheer,2 Amit Kumar Yadav,3 and Ashish Kumar Mandal4